Document downloaded from http://www.revespcardiol.org, day 25/05/2013. This copy is for personal use. Any transmission of this document by any media or format is strictly prohibited.

The main findings of this study indicate that 6% of students with no apparent cardiovascular disease had iLVM with shortening of the circumferential and longitudinal fibers as an expression of the deterioration in systolic function, and an increase in left ventricular diastolic pressure as an expression of diastolic dysfunction. These findings were independent of family history of cardiovascular RF, blood pressure, or anthropometric variables. The persistence of increased LVM in the group with iLVM when adjustments were made for different covariables indicates an inadequate response. The reduction in S' and Vcf in young people with iLVM is an important indication of a general abnormality of the myocardial fibers and is associated with lower afterload following similar preload when compared with the group with aLVM. This finding is indicative of inotropism. Although the absolute values of E/e' in our study are within the normal range, the increase observed in individuals with iLVM would suggest a slight increase in ventricular filling pressure as an expression of early changes in diastolic function. Although the cross-sectional nature of the study makes it impossible to determine the risk of cardiovascular events in the population studied, the emerging phenotype of the individuals with iLVM is similar to that previously shown in adults, where it was associated with increased risk.[3,4] These findings support the concept of an inadequate response in the development of iLVM, described here for the first time in young adults. Longitudinal studies are now required to assess the prognostic impact of this subclinical marker of compromised cardiac function in similar populations.

Eduardo M. Escudero,* Oscar A. Pinilla, and Irene L. Ennis

Centro de Investigaciones Cardiovasculares, Facultad de Ciencias Médicas, Universidad Nacional de La Plata, La Plata, Buenos Aires, Argentina

*Corresponding author:
E-mail address: emescu@gmail.com (E.M. Escudero).

Available online 23 May 2012

REFERENCES

1. De Simone G, Pasanisi F, Contaldo F. Link of nonhemodynamic factors to hemodynamic determinants of left ventricular hypertrophy. Hypertension. 2001;38:13–8.
2. Koren MJ, Devereux RB, Casale PN, Savage DD, Laragh JH. Relation of left ventricular mass and geometry to morbidity and mortality in uncomplicated essential hypertension. Ann Intern Med. 1991;114:345–52.
3. Muiesan ML, Salvetti M, Paini A, Monteduro C, Galbassini G, Bonzi B, et al. Inappropriate left ventricular mass changes during treatment adversely affects cardiovascular prognosis in hypertensive patients. Hypertension. 2007;49:1077–83.
4. Celentano A, Palmieri V, Esposito ND, Pietropaolo I, Crivaro M, Mureddu GF, et al. Inappropriate left ventricular mass in normotensive and hypertensive patients. Am J Cardiol. 2001;87:361–3.
5. Devereux RB, Alonso DR, Lutas EM, Gottlieb GJ, Campo E, Sachs I, et al. Echocardiographic assessment of left ventricular hypertrophy: comparison to necropsy findings. Am J Cardiol. 1986;57:450–8.

doi:10.1016/j.rec.2012.01.014

Brugada Electrocardiogram Pattern Induced by Cannabis

Patrón electrocardiográfico de Brugada inducido por cannabis

To the Editor,

We describe a 42-year-old man with repeated use of cannabis as the only history of interest. He had come to the emergency room twice in 3 months for palpitations immediately after using moderate doses of the drug. An electrocardiogram (ECG) was performed at both visits. On the first occasion, no abnormalities were described; however, on the second, the ECG showed type I Brugada ECG pattern (BEP) (Figs. 1 and 2) and frequent premature ventricular beats (right ventricular outflow tract morphology). The presence of fever or other situations or substances that could induce BEP was excluded. The patient was advised to cease using the drug and was referred to our clinic. The patient, remaining abstinent, presented a normal ECG in the clinic. When the V_1 and V_2 leads were placed in the second intercostal space, type III BEP was observed (Fig. 2). The previous emergency room ECGs were reviewed, and type I BEP was found on the first occasion. The echocardiogram and Holter recording were normal.

We reviewed the literature to search for any relationship between cannabis and Brugada syndrome.[1,2] We found only 1 case study which described the appearance of BEP after acute cannabis-induced intoxication in a young patient but concluded that the case did not exhibit a true Brugada pattern, as procainamide testing was negative. For this reason, we decided to carry out a flecainide test to exclude that our case was similar.

In the flecainide test, the patient presented type III BEP at baseline. The infusion was prematurely stopped when type I BEP appeared. Therefore, it was concluded that the patient presented asymptomatic BEP (in the absence of syncope, family history of sudden death, or other risk criteria), and that the BEP does not appear spontaneously, but only after cannabis exposure, hence he was a low-risk patient.

The cannabis prohibition was maintained, and at the subsequent follow-up visit, the patient had remained abstinent. There were no clinical manifestations. At a total of 4 visits following cannabis cessation, the patient showed no type I BEP (normal ECG on 2 occasions; type III pattern on 2 occasions).

Our case raises the issue of a possible interaction between cannabis and manifestations of Brugada syndrome.

It could be argued that the patient had intermittent type I BEP and that the relationship between the appearance of this pattern and prior cannabis use was fortuitous, although this is rather unlikely. Hypothetically, reproducibility of the ECG abnormalities could be confirmed by controlled exposure of the patient to cannabis. Because the drug is illegal and potentially addictive, however, the test would raise ethical and legal problems. Moreover, there is a lack of experience with the performance and interpretation of this type of experiment (necessary dose, safety, sensitivity, specificity).

An additional argument is that the literature contains no similar descriptions and the mechanisms of the interaction are unclear. A late vagotonic effect after cannabis exposure has been described, and vagal tone is one of the situations that can unmask BEP.[3,4] Cannabinoids have also been reported to block Kv1.5 cardiac potassium channels,[5] although this effect does not appear to explain the appearance of BEP.

In light of the results described and until new evidence is available, we considered prudent to add cannabis to other drugs and toxic substances that should be avoided by patients with BEP at our hospital.

Document downloaded from http://www.revespcardiol.org, day 25/05/2013. This copy is for personal use. Any transmission of this document by any media or format is strictly prohibited.

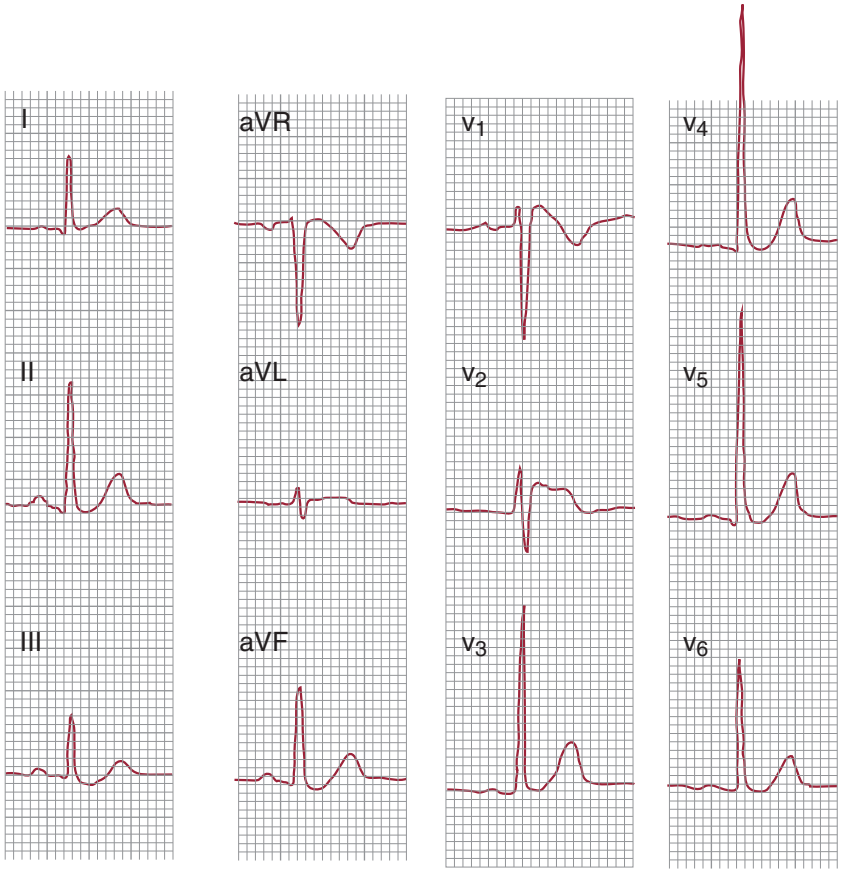

Figure 1. Twelve-lead electrocardiogram showing type I Brugada pattern (obtained when the patient came to the emergency room after cannabis use).

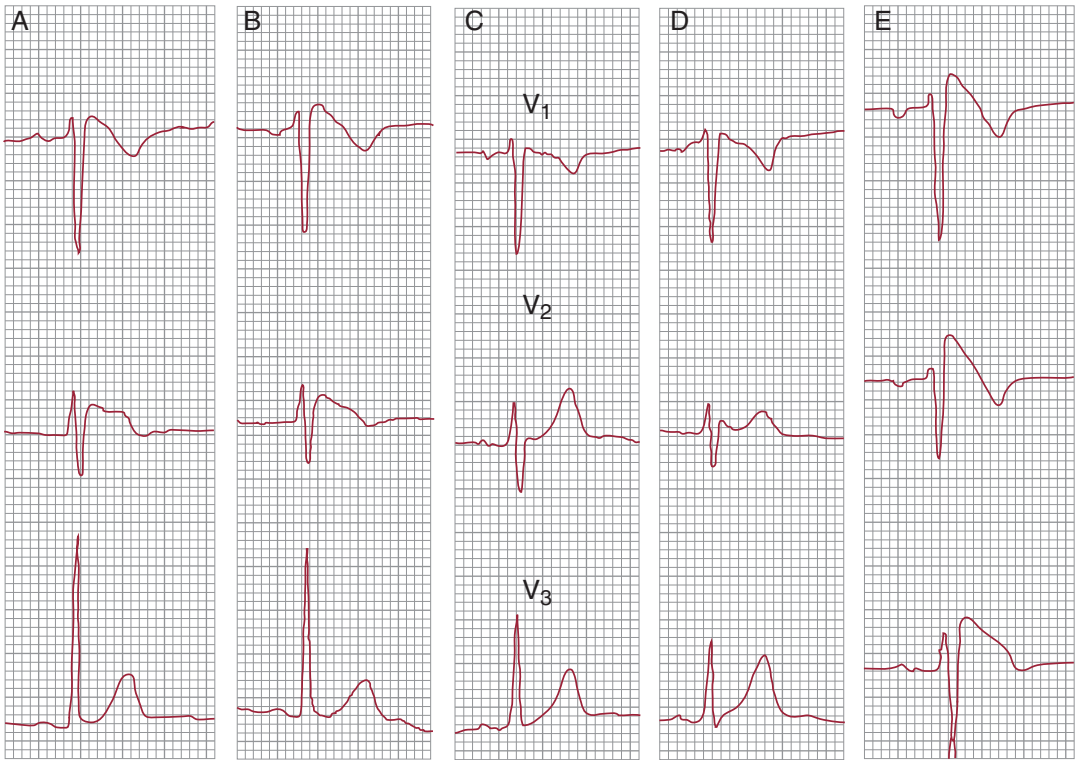

Figure 2. Electrocardiogram (V_1-V_3 leads). A and B, type I Brugada pattern that appeared at 2 visits in the emergency room after cannabis exposure. C and D, electrocardiogram in the outpatient clinic, no recent use. In D, the V_1 and V_2 leads were raised to the second intercostal space and type III Brugada pattern was observed. E, V_1-V_3 leads during flecainide infusion; type I Brugada pattern.

Document downloaded from http://www.revespcardiol.org, day 25/05/2013. This copy is for personal use. Any transmission of this document by any media or format is strictly prohibited.

Antonio J. Romero-Puche,[a,*] Natalia Trigueros-Ruiz,[b] M. Carmen Cerdán-Sánchez,[a] Fernando Pérez-Lorente,[a] Diego Roldán,[a] and Tomás Vicente-Vera[a]

[a]*Servicio de Cardiología, Hospital General Universitario Reina Sofía, Murcia, Spain*
[b]*Servicio de Urgencias, Hospital General Universitario Reina Sofía, Murcia, Spain*

* Corresponding author:
E-mail address: antoniojoserp@hotmail.com (A.J. Romero-Puche).

Available online 28 April 2012

REFERENCES

1. Daccarett M, Freih M, Machado C. Acute cannabis intoxication mimicking Brugada-like ST segment abnormalities. Int J Cardiol. 2007;119:235–6.
2. Postema PG, Wolpert C, Amin AS, Probst V, Borggrefe M, Roden DM, et al. Drugs and Brugada syndrome patients: review of the literature, recommendations, and an up-to-date website (www.brugadadrugs.org). Heart Rhythm. 2009;6:1335–41.
3. Ghuran A, Nolan J. Recreational drug misuse: issues for the cardiologist. Heart. 2000;83:627–33.
4. Benito B, Brugada J, Brugada R, Brugada P. Síndrome de Brugada. Rev Esp Cardiol. 2009;62:1297–315.
5. Barana A, Amorós I, Caballero R, Gómez R, Osuna L, Lillo MP, et al. Endocannabinoids and cannabinoid analogues block cardiac hKv1.5 channels in a cannabinoid receptor-independent manner. Cardiovasc Res. 2010;85:56–67.

doi:10.1016/j.rec.2012.01.015

Cardiac Troponin I Increases in Female Adventure Racers

Elevación de la troponina cardiaca I en corredoras de raids de aventura

To the Editor,

Although exercise can reduce the incidence of cardiovascular disease by between 33% and 50%,[1–3] intense or prolonged exercise can increase cardiac troponin (cTn) levels in individuals with no coronary obstruction.[4] Understanding the significance of elevated cTn could prevent unnecessary or invasive procedures in athletes. The objective of this study was to determine the behavior of cardiac troponin I (*c*TnI) in women participating in adventure races.

In the Women International Adventure Raid, participants cover a distance of 80 km with an elevation gain of 2600 m. The race includes sections of swimming, running, and cycling. Before the race, study participants completed an interview to collect data on age, weight, height, body mass index (BMI), toxic habits, medical history, medications, weekly training time, and nutrition. Blood tests were also performed.

Data collected after the event included the contestants' race time and any symptoms appearing during it. A second blood test was performed and glucose, cholesterol, triglyceride, high density lipoprotein cholesterol (HDL-C), low density lipoprotein cholesterol (LDL-C), creatine kinase (CK), and serum cTnI levels before and after the race were measured. An increase in cTnI was defined as ≥0.04 ng/mL.

Blood test results were compared using non-parametric tests. A logistic regression analysis was used to analyze the influence of different variables on elevated troponin levels.

Of the 50 riders who entered the race, 34 (68%) participated in the study. Median age was 32.5 [30-35.25] years; BMI was 21.44 [20.28-22.34]. Median weekly training and race times were 8.5 [5.37-12] h and 618 [610-629.25] min, respectively.

None of the racers reported symptoms of heart disease during the race.

At the end of the race, troponin I levels had increased significantly, by 0.03 [0.01-0.08] ($P<.001$); a moderate increase (≥0.04 ng/mL and ≤0.5 ng/mL) was observed in 14 runners (41.18%), and a >0.5 ng/mL (0.76 ng/mL) increase was observed in one case.

Significant increases were recorded in HDL-c (8.6 [5.15-11.53] mg/dL; $P<.001$), glucose (12 [7-31] mg/dL; $P=.013$), and CK (402 [227-668] mg/dL; $P<.001$). No increase was observed in any of the other variables (Table 1).

There was a statistically significant correlation between increased CK and race time (r=0.408; $P=.017$), but not between cTnI and CK, hours of training, or race time (Table 2). Finally, there was a negative correlation between LDL-C and increased cTn1.

The release of cTn secondary to myocardial injury can be due to ischemia from rupture of arterial plaque and coronary occlusion, ischemia without atherosclerosis, increased myocardial oxygen demand, and non-ischemic injury or direct damage (trauma, myocarditis or cardiotoxicity from drugs).[5] These do not explain the release of cTn in healthy subjects after exercise.

Several studies have shown cTn elevations in sports in which cardiac output, heart rate, and blood pressure remain high for hours, such as marathons, ultra marathons, triathlons, and cycling.[4,5]

This elevation could be due to damage to cardiomyocytes from the sustained increase in cardiac work rate combined with the physiological environment existing in situations of prolonged exercise (altered pH, increased core temperature, etc.).

Table 1
Pre- and Post-Race Troponin, Creatine, Glucose, and Lipid Values

	Pre-race	Post-race	*P*
Troponin I	0 [0-0.01]	0.04 [0.02-0.08]	<.0005
CK	101 [72-122]	474 [345-845]	<.0005
Blood sugar	88 [82-100]	103 [85-117]	.0130
Total cholesterol	176 [152-200]	182 [162-203]	.1200
Triglycerides	69 [53-89]	59 [48-74]	.1460
HDL-C	59 [49-71]	69 [60-78]	<.0005
LDL-C	100 [84-121]	99 [88-114]	.1020

CK, creatine kinase; HDL-C, high density lipoproteins cholesterol; LDL-C, low density lipoproteins cholesterol.
Data are medians [interquartile range].

Table 2
Spearman Correlations (*P*) Between Increased Cardiac Troponin I and Creatine Kinase, and Other Variables

	Elevated cardiac troponin I	Elevated CK
Age	−0.123 (0.488)	−0.164 (0.354)
BMI	0.136 (0.443)	−0.025 (0.889)
Weekly training time (h)	0.159 (0.369)	−0.144 (0.415)
Race time (min)	0.176 (0.391)	0.408 (0.017)
Elevated glucose	0.180 (0.309)	−0.256 (0.144)
Elevated LDL-C	−0.532 (0.001)	−0.140 (0.429)
Elevated HDL-C	−0.298 (0.087)	0.001 (0.997)
Elevated triglycerides	0.207 (0.240)	−0.234 (0.182)
Elevated cardiac troponin I	—	0.206 (0.241)

BMI, body mass index; CK, creatine kinase; HDL-C, high density lipoproteins cholesterol; LDL-C, low density lipoproteins cholesterol.