Document downloaded from http://www.elsevier.es, day 20/05/2013. This copy is for personal use. Any transmission of this document by any media or format is strictly prohibited.

Rev Esp Cardiol. 2012;**65(5)**:470

Image in cardiology

An Unusual Case of Kartagener Syndrome

Un insólito caso de síndrome de Kartagener

Delicia I. Gentille-Lorente*

Servicio de Cardiología, Hospital de Tortosa Verge de la Cinta, IISPV, Tarragona, Spain

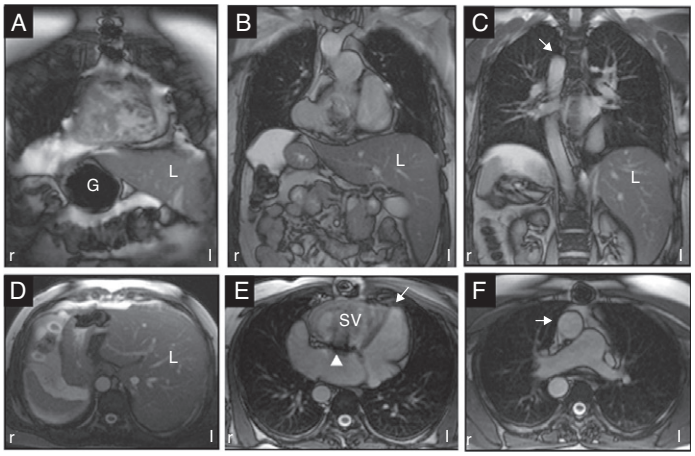

Figure 1.

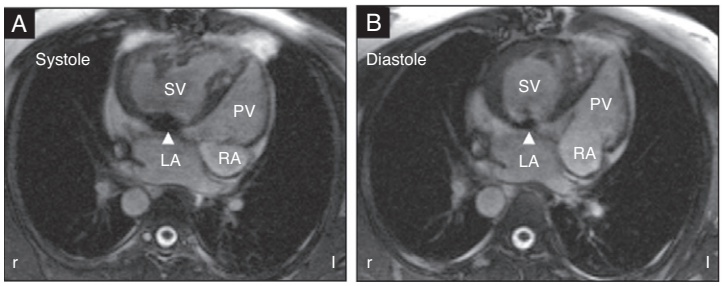

Figure 2.

A 45-year-old man had been diagnosed of Kartagener syndrome (KS) in infancy, involving *situs inversus* or "mirror" position of the abdominal organs (cardiac magnetic resonance images: Figs. 1A, B, C and D. L, liver; G, gastric fundus) with levocardia (Fig. 1E, arrow), associated with congenitally corrected transposition of the great arteries (CTGA), and right aortic arch (Figs. 1C and F, arrow). The anatomic pattern of CTGA was visceroatrial situs inversus (I), ventricular D-loop with atrioventricular and ventriculoarterial discordance (D), and D-transposition of the great arteries (D) (Fig. 1F). Owing to severe failure of the systemic atrioventricular valve and dysfunction of the systemic ventricle, the patient required valve replacement surgery at age 38 years. A metal prosthesis was implanted without complications (Figs. 1E, 2A and B, arrowhead. SV, systemic ventricle; PV, pulmonary ventricle; LA, left atrium; RA, right atrium). Since that time, he has undergone periodic follow-up and has remained asymptomatic.

Kartagener syndrome is a recessive autosomal genetic condition with an incidence of 1 case in 32 000 to 68 000 live births. It is characterized by the triad of situs inversus (often with dextrocardia), chronic sinusitis, and bronchiectasis. An uncommon anomaly that accounts for less than 1% of all congenital heart diseases, CTGA occurs in a typical criss-cross pattern (S, L, L). However, in the rare cases associated with KS showing situs inversus and dextrocardia, the expected pattern is I, L, L.

The patient described is the first reported case of KS with levocardia associated with CTGA (I, D, D), right aortic arch, and valve replacement.

* Corresponding author:
E-mail address: dgentille.ebre.ics@gencat.cat
Available online 16 April 2011

1885-5857/$ – see front matter © 2010 Sociedad Española de Cardiología. Published by Elsevier España, S.L. All rights reserved.
doi:10.1016/j.rec.2010.08.011