

NEUROLOGÍA

www.elsevier.es/neurologia



LETTERS TO THE EDITOR

Importance of electromyography studies in the diagnosis of orthostatic tremor

Importancia del estudio electromiográfico en el diagnóstico del temblor ortostático

Sir,

We present the case of a female patient of 47 years of age with a history of TBC treated in childhood and trauma due to a traffic accident at age 34, requiring surgery on the left meniscus; gastric neoplasia at 44 years of age, requiring total gastrectomy, cholecystectomy and a monthly provision of vitamin B₁₂, without chemotherapy or radiotherapy.

Since her road accident at 34 years of age, she reports clinical signs of instability in the lower limbs, initially when standing and at rest, which has gradually evolved to affect her gait also to the point of preventing her from walking and necessitating a wheelchair in the last six months (13 years after onset). Since one year ago she has had difficulty holding heavy objects with her upper limbs.

The neurological examination revealed no motor or sensory deficit and her osteotendinous reflexes are present and symmetrical. Moderate bilateral postural tremor is observed, along with rigidity, moderate global bradykinesia and slow gait.

The simultaneous electromyographic recording of muscle activity with cutaneous electrodes on both anterior tibialis and gemellus muscles shows an absence of activity when sitting, and the presence of salvos of synchronous muscular activity in agonists and antagonists when standing, at a frequency of 16 Hz concordant with the clinical suspicion of orthostatic tremor (fig. 1).

In the upper limbs, she presents electromyographic activity compatible with tremor at 16 Hz synchronously between extensors and flexors of the fingers during isometric contraction (postural manoeuvres associated with holding a weight), which disappears during any kind of isotonic activation such as intermittent flexion and extension of the elbows (eating and drinking).

NMR and datascan were normal. The patient had received treatment with biperiden, clonazepam,

carbamazepine, pramipexole and gabapentin without any clear improvement.

Orthostatic tremor (OT) is an infrequent motor disorder first described by Heilman in 1984.¹ It is characterized by a sensation of instability when standing, which improves on sitting or walking. The few clinical findings, when present, are limited to small visible or merely palpable contractions in the lower limbs in when standing.²⁻⁴

OT is considered to be an idiopathic disorder, as the study with cerebral neuroimaging and other examinations are generally normal. Patients suffering from OT can be divided into 2 sub-groups: "primary OT" with or without postural tremor of the upper limbs and "OT plus" in which it is associated with other movement disorders such as Parkinson's disease, restless legs syndrome or dyskinesias.³ Some cases have also been described as associated with protuberant lesions.⁵

The diagnosis is confirmed only by electromyographic recording of characteristic rhythmical discharges of muscle activity (tremor) between 13 and 18 Hz.²

Its pathophysiological characteristics of interest are the presence of this pattern more evidently in the muscles of the lower limbs during orthostatism, which may also be present in the trunk and the upper limbs when holding a weight or in isometric contraction, and even in cranial muscles.^{3,4}

It is thought that OT is generated by a central oscillator of unknown location, as the electromyographic discharges are synchronous in all four limbs, the trunk and the facial muscles. A reasonable location for this oscillatory system would be the centres regulating muscle tone and bipedestation in the brainstem, although the cerebral cortex, basal nodes and the cerebellum are believed to be involved in their pathogenesis and modulation.^{4,6}

Transcranial magnetic stimulation readjusts OT, implying that the cortical structures play an important role in the modulation of the activity of the neuronal networks generating the tremor. Transcranial magnetic stimulation acts by temporarily suppressing and modulating the tremor, as it initially reappears at a higher frequency than the pre-stimulus and subsequently returns gradually to its initial frequency⁶ (fig. 2A).

As other authors have shown⁷, by applying the back-averaging technique to the EEG activity we find a rhythmical cortical oscillation linked by time to the tremor in the lower limbs (fig. 2B).

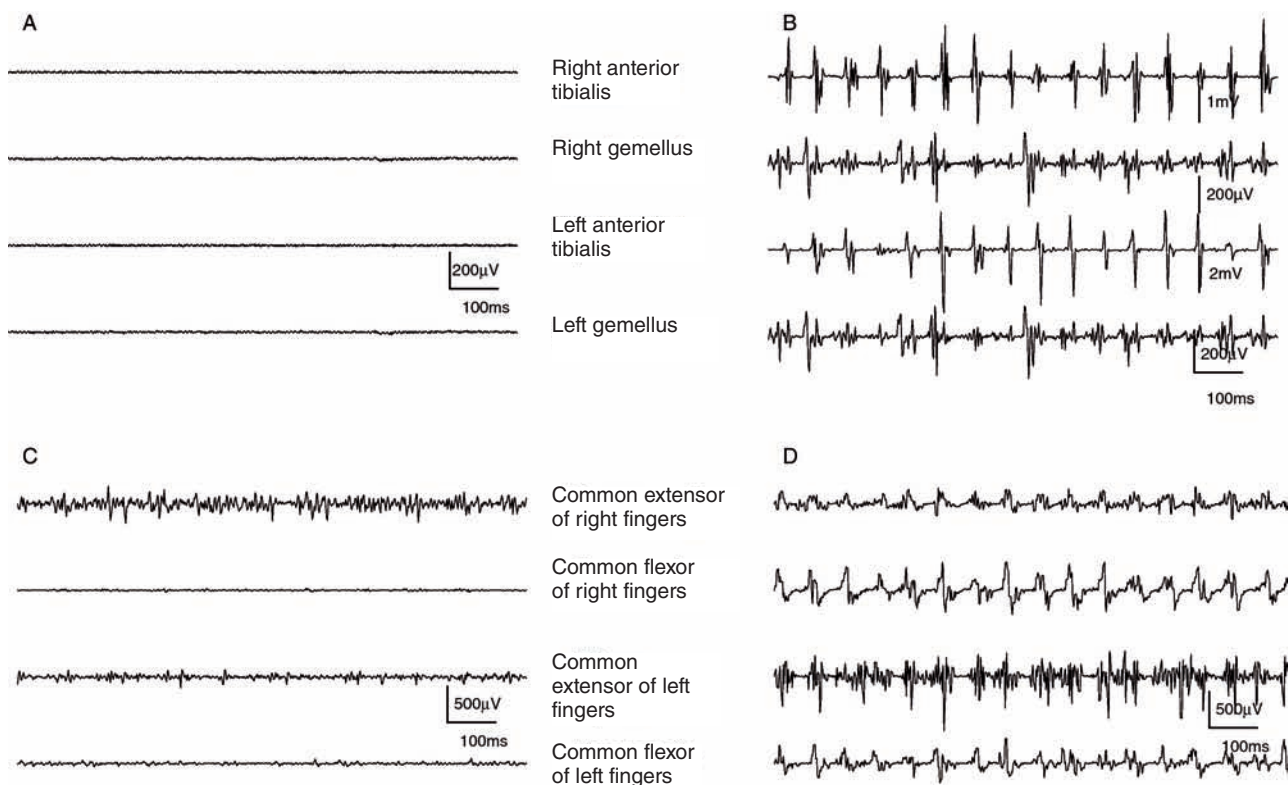


Figure 1 A: Absence of tremor when sitting. B: When standing, tremor at 16 Hertz. C: Drinking white coffee: absence of tremor. D: Upper limbs at 90° holding a heavy book. Presence of tremor at 16 Hz.

Various drugs have been used for the treatment of OT, including benzodiazepines, dopaminergic agents, anti-epileptics and beta blockers, with varying results. Of all of these, clonazepam seems to be the most effective. Despite the existence of evidence that the dopaminergic system may be involved in the pathogenesis of OT, the response to L-dopa or dopaminergic agonists is also

variable and usually occurs in a sub-group of patients with OT and associated Parkinson's disease (OT plus).²

In some severe cases of orthostatic tremor that do not respond to pharmacological treatments, some success has been achieved with deep brain stimulation at the level of the thalamus (VIM: *ventralis intermedius nucleus*).

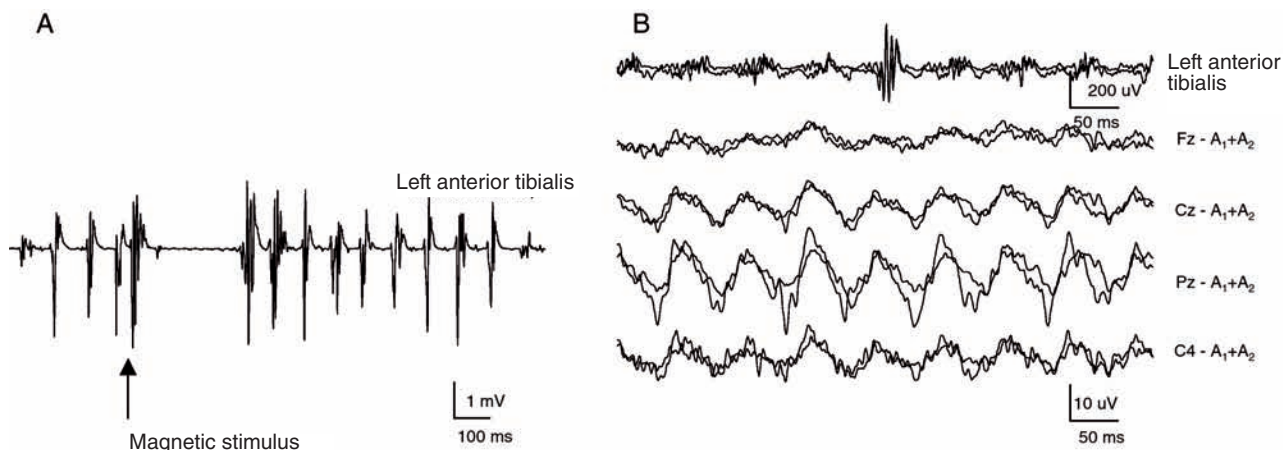


Figure 2 A: Modulation of orthostatic tremor with transcranial magnetic stimulation on the motor cortex. Recording of anterior tibialis muscle. B: Back-averaging showing synchronized oscillatory activity with tremor in the leg. Cz, Fz, Pz and C4: location of the recording electrodes according to the international 10/20 placement system. Reference A₁+A₂: linked ears.

In conclusion, we should like to highlight that, in patients with instability when trying to remain standing, we should suspect that orthostatic tremor may be involved, and an innocuous electromyographic study may lead us to confirm or rule out this diagnosis.

References

1. Heilman KM. Orthostatic tremor. *Arch Neurol.* 1984;41:880-1.
2. Deuschl G, Bain P, Brin M, and an Ad Hoc Scientific Committee. Consensus Statement of the movement disorder society on tremor. *Mov Disord.* 1998;13:2-23.
3. Gerschlager W, Münchau A, Katzenschlager R, Brown P, Rothwell JC, Quinn N, et al. Natural history and syndromic associations of orthostatic tremor: a review of 41 patients. *Mov Disord.* 2004;19:788-95.
4. Piboolnurak P, Yu QP, Pullman SL. Clinical and Neurophysiologic Spectrum of Orthostatic Tremor: Case Series of 26 Subjects. *Mov Disord.* 2005;20:1455-61.
5. Benito-León J, Rodríguez J, Ortí-Pareja M, Ayuso-Peralta L, Jiménez-Jiménez FJ, Molina JA. Symptomatic orthostatic tremor in pontine lesions. *Neurology.* 1997;49:1439-41.
6. Spiegel J, Fuss G, Krick C, Dillmann U. Impact of different stimulation types on orthostatic tremor. *Clin Neurophysiol.* 2004;115:569-75.
7. Guridi J, Rodríguez-Oroz Maria C, Arbizu J, Alegre M, Prieto E, Landeche I, et al. Successful Thalamic Deep Brain Stimulations for Orthostatic Tremor. *Mov Disord.* 2008;23(13):1808-11.

S. Yagüe*, M. Veciana, J. Pedro, J. Campdelacreu

Servicio de Neurología, Hospital Universitario de Bellvitge Príncipes de España, Hospitalet de Llobregat, Barcelona, Spain

*Corresponding author.

E-mail: syj180574@telefonica.net (S. Yagüe).
