Document downloaded from http://www.elsevier.es, day 24/05/2013. This copy is for personal use. Any transmission of this document by any media or format is strictly prohibited.

ORIGINAL PAPER

Behavior of the first cuneiform in the surgical correction of metatarsus adductus

J. Knörr[a], F. Accadbled[a], J. Jégu[b], A. Abid[a], J. Sales de Gauzy[a] and J.P.Cahuzac[a]
[a]*Service de Chirurgie Orthopédique et Traumatologie Pédiatrique. Hôpital des Enfants. Centre Hospitalier Universitaire de Toulousse. Toulousse. France.*
[b]*Service d'Epidemiologie. Centre Hospitalier Universitaire de Toulousse. Toulousse. France*

Purpose. Metatarsus adductus is an adduction deformity of the forefoot. Our purpose is to uphold the claim that the main anomaly is to be found on the cuneiform side of the cuneo-metatarsal joint and that the growth of the medial cuneiform is fundamental for correction further to capsulotomy.
Materials and methods. This is a radiological study of 23 children with idiopathic or clubfoot-related metatarsus adductus subjected between 1982 and 2000 to a release of the cuneiform metatarsal joint.
X-rays were taken of the 30 operated feet and of 12 contralateral feet used as controls. The following measurements were made: cuneiform-metatarsal angle, distal inclination angle of the medial cuneiform bone, angle formed between the latter surface and the first metatarsal and the proximal articular angle of the first metatarsal. The mean pre-op, immediate post-op and post-op final values of these angles were compared using the relevant statistical tests.
Results. As regards idiopathic metatarsus adductus, the cuneiform metatarsal angle went from a preop value of 150.4° to 170.2° at the end of follow-up; the distal inclination angle of the medial cuneiform went from 62° to 81.1°; and the angle formed between the latter surface and the first metatarsal and the proximal articular angle of the first metatarsal went from 88.4° to 89.1°.
With respect to clubfoot-related metatarsus adductus, the cuneiform metatarsal angle went from a preop value of 155.3° to 169.7°, the distal inclination angle of the medial cuneiform went from 61.9° to 79.7°, and the angle formed between the latter surface and the first metatarsal and the proximal articular angle of the first metatarsal went from 88.3° to 90°. On the healthy side, the angle values showed virtually no changes.
Conclusions. The obliqueness of the medial cuneiform-metatarsal joint is closely related to metatarsus adductus. Post-surgical correction also takes place at the expense of this bone, which tends to fill the space created by the capsulotomy.

Key words: *metatarsus adductus, medial cuneiform-metatarsal obliqueness, first cuneiform bone, capsulotomy.*

Comportamiento de la primera cuña en la corrección quirúrgica del metatarso adducto

Objetivo. El metatarso adducto (MTA) es una deformación en adducción del antepié. Nuestro objetivo es apoyar la hipótesis por la cual la principal anomalía se encuentra en el lado cuneiforme de la articulación cuneo-metatarsiana, y que el crecimiento de la primera cuña es fundamental en la corrección tras la capsulotomía.
Material y método. Se trata de un estudio radiológico realizado con 23 niños con MTA idiopático o secundario a pie zambo, operados entre los años 1982 y 2000, con liberación de la articulación cuneo-metatarsiana. Se realizaron radiografías de los 30 pies operados, y de 12 pies contralaterales utilizados como controles, con las siguientes mediciones: ángulo cuneo-metatarsiano (FMCA), ángulo de inclinación distal de la primera cuña (DCAA), ángulo entre esta superficie y la del primer metatarsiano (PENTE) y ángulo proximal articular del primer metatarsiano (PMAA). Se compararon las medias de estos ángulos tomadas en pre, post-operatorio inmediato y final del seguimiento, mediante los pertinentes tests estadísticos.
Resultados. Respecto al MTA idiopático, el FMCA aumentó de 150,4° en el preoperatorio a 170,2° al final, el DCAA pasó de 62° a 81,1°, y el PMAA de 88,4° a 89,1°. Respecto al MTA secundario a pie zambo, el FMCA aumentó de 155,3° a 169,7°, el DCAA pasó de 61,9° a 79,7°, y el PMAA de 88,3° a 90°. En el lado sano los ángulos apenas se modificaron.
Conclusiones. La oblicuidad de la articulación cuneo-metatarsiana medial está estrechamente relacionada con el metatarso adducto. La corrección post-quirúrgica se hace tam-

Corresponding author:
J. Knörr.
Service de Chirurgie Orthopédique et Traumatologie Pédiatrique.
Hôpital des Enfants.
330 Avenue de Grande Bretagne.
31059 Toulouse.
E-mail: knorr.j@chu-toulouse.fr

Received: January 2006.
Accepted: February 2007.

Document downloaded from http://www.elsevier.es, day 24/05/2013. This copy is for personal use. Any transmission of this document by any media or format is strictly prohibited.

bién a expensas de este hueso, que tiende a rellenar el espacio creado por la capsulotomía.

Palabras clave: *metatarso adducto, oblicuidad cuneometatarsiana medial, primera cuña, capsulotomía.*

Metatarsus adductus (MTA) is characterized by a deformation of the adductus of the forefoot in relation to the hindfoot. The apex of this deformation is located in Lisfranc's joint. This condition may be idiopathic or secondary, as a component or as a sequelae of clubfoot.

Idiopathic MTA is the most frequent deformation seen in the foot[1], with an estimated incidence of 3%[2].

Its natural history is spontaneous correction in 95% of cases in isolated forms[2,3]. However, a severe residual adduction persists in 4-14%[2-4] of cases.

Metatarsus adductus (MTA) tends to persist in 16-81% of secondary forms[5,6]. Persistence of deformities of the middle metatarsals makes spontaneous correction more difficult after age 4.

The pathophysiology of MTA is a subject of controversy, which explains the number of surgical techniques proposed, such as joint release, soft tissue release, metatarsal ostetotomies or midtarsal osteotomies, or combinations of these.

Radiological studies, classically carried out by measuring the talus-first metatarsal angle, show an adduction of the first metatarsal greater than that of the others, but the most important abnormality is that the metatarsal-cuneiform joint is not oriented frontally, but «looks inwards». Farsetti et al[3] found this abnormality in 68% of the cases in their series, however, they were unable to consider it specific.

Our hypothesis is that in children under 6 years of age the release of the medial metatarsal-cuneiform joint, together with osteotomies of the middle metatarsals, makes it possible, by stimulating the growth of the cuneiform bone, to correct this deformity and stabilize the correction in a manner that is lasting over time.

MATERIALS AND METHODS

This is a study carried out in 23 children (13 boys and 10 girls) operated for MTA (Figure. 1). In 7 cases the deformity was bilateral, which means that a total of 30 feet were affected. According to the origin of the deformity, we divided the cases into 2 groups, idiopathic MTA (group 1) with 9 cases and MTA as a sequelae of clubfoot previously treated orthopedically (group 2), with 21 cases.

Selection was made on the basis of a minimum postoperative follow-up (5 years) and clinical history. We have not included the cases of children operated very early, in which the poor ossification of the first cuneiform does not make it possible to carry out radiological measurements.

Figure 1. *Unilateral metatarsus adductus foot (right).*

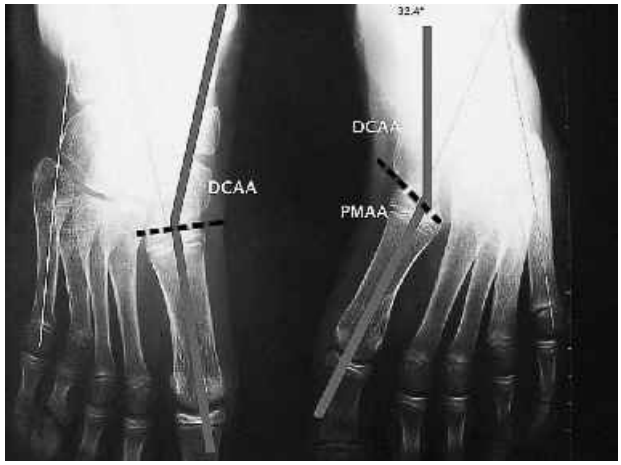

Figure 2. *Preoperative measurements on the affected and the healthy side. DCAA: distal cuneiform articular angle of the first cuneiform (in relation to its longer axis); PMAA: proximal metatarsal articular angle of the first metatarsal (in relation to its longer axis); The addition of both plus the virtual intra-articular angle (angle of aperture of the metatarsal-cuneiform) during the preoperative period (dotted line) results in the first metatarsal-cuneiform angle (FMCA).*

We compared these 30 pathological feet, before and after intervention, with the 12 originally healthy contralateral feet (for control purposes we did not take into account feet that became normal after orthopedic treatment of clubfoot).

Mean age (for each operated foot) at the time of surgery was 5 years and 4 months (3 years 3 months-10 years 0 months) in group 1, and 5 years and 6 months (3 years 2 months-10 years 0 months) in group 2. Mean follow-up was 150.6 months (61-283) in group 1 and 129.2 (60-275) in group 2.

For each foot, both in the active and control groups (42 feet in total), an antero-posterior weight-bearing x-ray was

Document downloaded from http://www.elsevier.es, day 24/05/2013. This copy is for personal use. Any transmission of this document by any media or format is strictly prohibited.

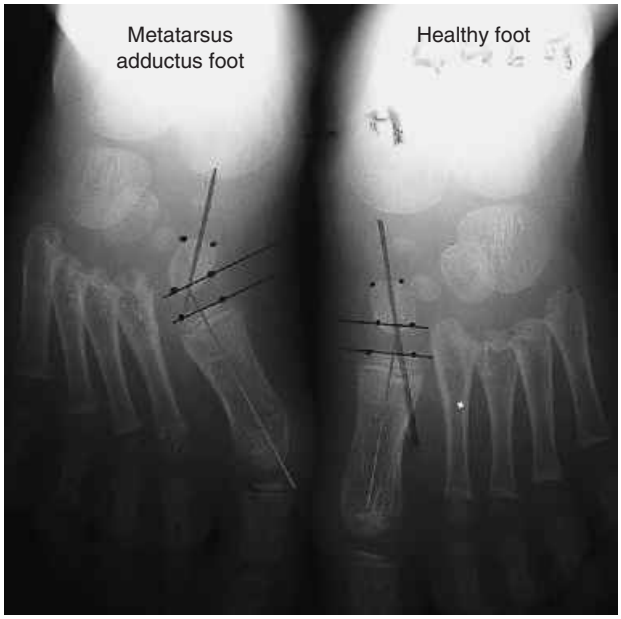

Figure 3. *Technique for angle measurement (in small children). The determination of 4 points that correspond to the vertices of the trapezoid of the cuneiform will help us define it for subsequent measurement, since in small children the cuneiform has a fairly ellipsoidal shape (Metatarsus adductus foot/Healthy foot).*

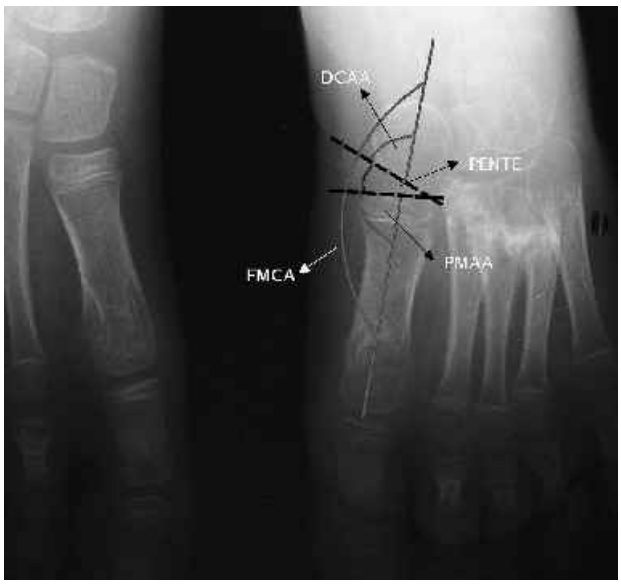

Figure 4. *Intra-articular angle (MCAA) during the postoperative period, once the osteosynthesis material has been withdrawn (dotted lines). This angle will be progressively filled in by the cuneiform, a process that will tend to maintain reduction stable for some time. DCAA: distal cuneiform articular angle during the preoperative period; FMCA: first metatarsal cuneiform angle during the immediate postoperative period; PMAA: proximal metatarsal articular angle during the preoperative period.*

taken during the immediate post-operative period and at the end of follow-up. We have registered the following radiological measurements (Figures. 2, 3, 4 and 5):

Figure 5. *Measurement of postoperative angles at the end of follow-up of the operated foot and the control foot.*

Figure 6. *Surgical technique (Cahuzac): metatarsal-cuneiform capsulotomy and osteotomies of the middle metatarsals. Fixation with Kirschner wires.*

The first metatarsal cuneiform angle (FMCA)[3], can be used as a measurement of MTA. The angle is made up of the greater axis of the first cuneiform and the first metatarsal, which, measured during the immediate preoperative period and at the end of the follow-up, is equivalent to the sum of the 3 angles also measured and described below:

1) Distal cuneifom articular angle (DCAA)[7]: which measures the distal obliquity of the cuneiform. This is formed by the greater axis of the first cuneiform with rela-

Document downloaded from http://www.elsevier.es, day 24/05/2013. This copy is for personal use. Any transmission of this document by any media or format is strictly prohibited.

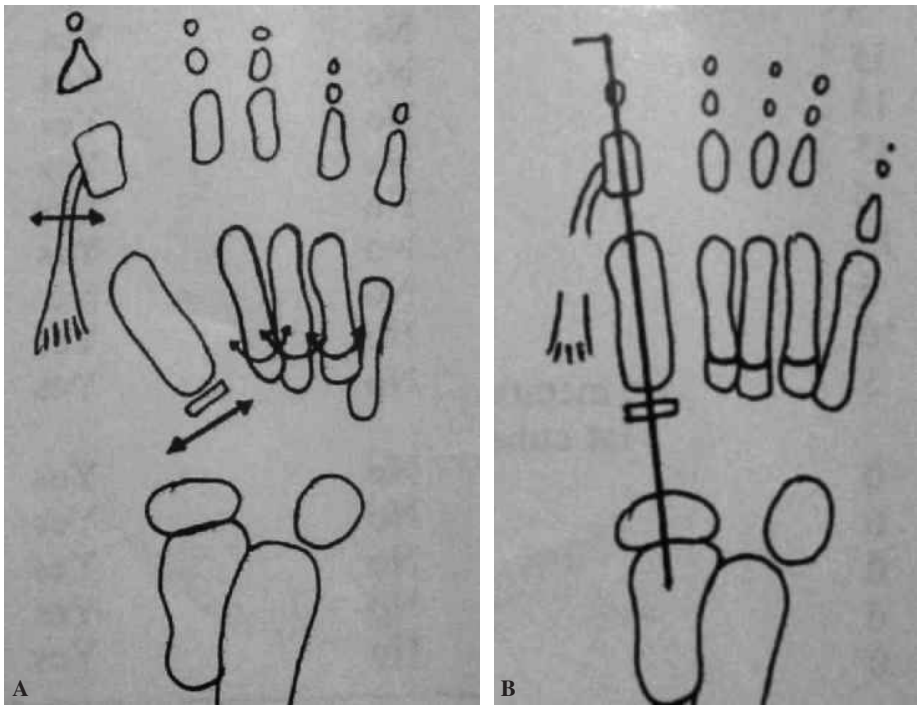

Figure 7. *Diagrams of the Cahuzac technique. (A) First part. (B) Second part.*

tion to the corresponding line on the distal articular surface of the cuneiform. It is measured during the preoperative period and at the end of follow-up.

2) Metatarsal-cuneiform aperture angle (MCAA): we have designed this angle formed by the line of the distal articular surface of the cuneiform and the line of the proximal articular surface of the first metatarsal. We have not found any references to this angle in the literature. Measurements were taken at three points in time: during the preoperative period, the immediate postoperative period and at the end of follow-up.

3) Proximal metatarsal articular angle (PMAA)[8]: which measures the obliquity of the base of the first metatarsal, and is formed by the proximal articular line of the first metatarsal and its greater axis. This was measured during the preoperative period and at the end of follow-up.

We have calculated the mean arithmetic value for each angle, using the healthy contralateral foot as a source of data for comparison. We have also carried out a statistical study comparing mean values using Student's «t» test or the Wilcoxon rank test if the former was not applicable. A correlation analysis was also performed to determine the relation between the MCAA, ‰DCAA and ‰PMAA angles.

The surgical technique[9] (Figures. 6, 7 and 8), always carried out by the same surgeon, consists of a dorsal incision with an upper, medial and inferior metatarsal-cuneiform capsulotomy, section of the *hallux* abductor and curved osteotomy of the base of the second metatarsal. Through a second dorsal incision an osteotomy of the base

Figure 8. *Postoperative X-ray.*

Document downloaded from http://www.elsevier.es, day 24/05/2013. This copy is for personal use. Any transmission of this document by any media or format is strictly prohibited.

Table 1. Main data seen in this study in the idiopathic metatarsus adductus

Pat	Sex	DOB	Diag	Age s	Fu (m)	DCAA	P	FMAA	EMCA	Pc	FMCAc	DCAAf	Pf	PMAAf	FMCAf
Affected side (idiopathic metatarsus adductus = group 1)															
22 DC	F	Jun-81	MTA R-B	3A3M	147	70	0	90	160	14	174	80	0	90	170
23 CD	M	Jun-80	MTA R-B	6A1M	61	76	0	86	162	20	182	90	0	86	176
24 CD	M	Jun-80	MTA L-B	6A1M	61	70	0	86	156	24	180	90	0	84	174
25 LR	M	Sep-75	MTA R 7	A11M	87	60	0	90	150	30	180	90	0	86	176
26 GC	F	Jun-79	MTA R	3A4M	283	64	0	84	148	30	178	74	0	90	164
27 MV	F	Mar-89	MTA R-B	5A3M	175	64	0	90	154	26	180	80	0	90	170
28 MV	F	Mar-89	MTA L-B	5A3M	175	50	0	90	140	40	180	78	0	90	168
29 LM	M	Jan-80	MTA R	5A0M	244	54	0	90	144	36	180	78	0	90	168
30 EA	M	Jun-85	MTA R-B	10A-0M	122	50	0	90	140	24	164	70	0	96	166
MEAN		Aug-82		5A-4M	150.6	62	0	88.4	150.4	27.1	177.6	81.1	0	89.1	170.2
Control side															
1 MA	F	Dec-89	N foot	6A5M	60	80	0	92	172			80	0	92	172
2 LW	M	Oct-83	N foot	5A0M	60	76	6	94	176			78	0	96	174
3 DC	F	May-79	N foot	4A7M	135	72	16	88	176			78	0	90	168
5 UJ	M	May-94	N foot	6A5M	60	84	0	90	174			90	0	80	170
6 RG	M	Oct-89	N foot	4A3M	61	70	10	88	168			74	0	90	164
7 BC	F	Mar-87	N foot	6A1M	149	70	0	98	168			76	0	100	176
11 CM	F	Aug-90	N foot	5A2M	60	74	0	90	164			74	0	90	164
16 RP	M	Apr-77	N foot	4A11M	135	70	0	84	164			76	0	84	160
17 GA	M	Jul-81	N foot	3A2M	141	80	0	94	174			70	0	94	164
25 LR	M	Sep-75	N foot	7A11M	87	78	0	90	168			72	0	90	162
26 GC	F	Jun-79	N foot	3A4M	283	82	0	86	168			66	0	90	156
29 LM	M	Jan-80	N foot	5A0M	244	78	0	86	164			72	0	86	158
MEAN		Jan-84		5A8M	122.9	76.2	2.7	90	169.7			75.5	0	90.2	165.7

DCAA: distal cuneiform articular angle during the preoperative period; DCAAf: distal cuneiform articular angle at the end of the followup; Diag: diagnosis; Age s: surgical age; DOB: date of birth; FMCA: first metatarsal cuneiform angle during the preoperative period; P: metatarsal-cuneiform aperture angle during the preoperative period; FMCAc: first metatarsal cuneiform angle during the immediate postoperative period; FMCAf: first metatarsal cuneiform angle at the end of the follow-up period; Pac: patient; Pc: metatarsal-cuneiform aperture angle during the immediate postoperative period; Pf: metatarsal-cuneiform aperture angle at the end of the follow-up period; N foot normal foot; PMAA: preoperative metarsal articular angle; PMAAf: metatarsal articular angle at the end of follow-up; MTA R: right idiopathic metatarsus adductus; MTA R-B: right idiopathic metatarsus adductus (originally bilateral); MTA L-B: left idiopathic metatarsus adductus (originally bilateral); Sex: sex; t (m): time of follow-up (months).

of the third and fourth metatarsals is performed. The reduction is stabilized by means of a Kirschner wire from the first metatarsal to the tarsus and the use of a cast for 45 days.

RESULTS

Affected Foot

The results can be seen in tables 1 and 2 and in Figures 9 and 10.

The FMCA in group 1 increased from a mean of 150.4° during the preoperative period to 170.2° (‰FMCA +19,8°) at the end of the follow-up period.

For group 2, the FMCA increased from 155.3° to 169.7° (‰FMCA +14.4°) a the end of the follow-up period.

The DCAA increased from 62° in the preoperative period to 81.1° at the end of the follow-up period (‰DCAA +19,1°), in group 1.

In group 2, this angle increased from 61.9° to 79.7° (‰DCAA +17.8°).

The PMAA increased from 88.4 to 89.1 at the end of the study (‰PMAA +0.7°), in group 1.

And in group 2, this value increased from 88.3° to 90.0° (‰PMAA +1.7).

The MCAA angle increased from 0° in the preoperative period to 27,1° (+27,1°) in the immediate postoperative period (surgical aperture of the metatarsal-cuneiform) and 0° (‰MCAA –27,1°) at the end of the follow-up period in group 1.

In group 2 this angle increased from 5.3° to 28.6° (+23.3°) in the immediate postoperative period and became 0° (‰MCAA –28.6°) at the end of the study. (These preoperative 5.3° are not due to joint aperture, but to a discrete bone divergence between the ellipsoidal process of the first cuneiform, seen in young cases, and the trapezoidal process of the base of the first metatarsal).

Document downloaded from http://www.elsevier.es, day 24/05/2013. This copy is for personal use. Any transmission of this document by any media or format is strictly prohibited.

Table 2. Main data seen in this study in the metatarsus adductus secondary to clubfoot

Pat	Sex	DOB	Diag	Age s	Fu (m)	DCAA	P	PMAA	EMCA	Pc	FMCAc	DCAAf	Pf	PMAAf	FMCAf
Affected side (metatarsus adductus secondary to clubfoot = group 2)															
1 MA	F	Dec-89	CF R	6A5M	60	72	0	88	160	20	180	84	0	88	172
2 LW	M	Oct-83	CF L	5A0M	60	64	6	90	160	30	184	86	0	92	178
3 DC	F	May-79	CF L	4A7M	135	50	16	94	160	30	174	76	0	96	172
4 BM	M	Dec-92	CF R-B	5A5M	89	68	0	88	156	30	186	82	0	88	170
5 UJ	M	May-94	CF L	6A5M	60	68	6	90	164	26	184	80	0	90	170
6 RG	M	Oct-89	CF R	4A3M	61	54	10	86	150	34	174	72	0	90	162
7 BC	F	Mar-87	CF L	6A1M	149	60	18	86	164	36	182	76	0	94	170
8 ZJ	M	Oct-86	CF R-B	0A0M	75	66	0	90	156	24	180	90	0	90	180
9 VM	M	Aug-86	CF R-B	5A1M	143	60	4	88	148	24	168	84	0	90	174
10 VM	M	Oct-86	CF L-B	5A1M	143	66	4	90	160	20	176	78	0	90	168
11CM	F	Aug-90	CF L	5A2M	60	64	0	88	152	22	154	90	0	90	180
12 RC	M	Aug-87	CF R-B	6A1M	114	44	20	84	148	50	178	68	0	90	158
13 RC	M	Aug-97	CF L-B	6A1M	114	44	24	88	156	40	172	80	0	90	170
14 PS	F	Aug-84	CF R-B	6A4M	60	60	4	90	154	34	184	76	0	90	166
15 PS	F	Aug-84	CF L-B	6A4M	60	56	0	96	152	28	180	74	0	96	170
16 RP	M	Apr-77	CF L	4A11M	135	70	0	86	156	24	180	78	0	84	162
17 GA	M	Jul-81	CF R	3A2M	141	70	0	90	160	20	180	70	0	94	164
18 RS	F	Sep-78	CF R-B	4A0M	275	64	0	86	150	30	180	82	0	90	172
19 RS	F	Sep-78	CF L-B	4A0M	275	68	0	86	154	24	178	86	0	82	168
20 AL	F	Oct-78	CF R-B	5A11M	252	68	0	84	152	24	176	84	0	86	170
21 AL	F	Oct-78	CF L-B	5A11M	252	64	0	86	150	30	180	78	0	90	168
		jul-85		5A-6M	129.2	61.9	5.3	88.3	155.3	28.6	177.6	79.7	0	90	169.7
Control side															
1 MA	F	Dec-89	N foot	6A5M	60	80	0	92	172			80	0	92	172
2 LW	M	Oct-83	N foot	5A0M	60	76	6	94	176			78	0	96	174
3 DC	F	May-79	N foot	4A7M	135	72	16	88	176			78	0	90	168
5 UJ	M	May-94	N foot	6A5M	60	84	0	90	174			90	0	80	170
6 RG	M	Oct-89	N foot	4A3M	61	70	10	88	168			74	0	90	164
7 BC	F	Mar-87	N foot	6A1M	149	70	0	98	168			76	0	100	176
11 CM	F	Aug-90	N foot	5A2M	60	74	0	90	164			74	0	90	164
16 RP	M	Apr-77	N foot	4A11M	135	70	0	84	164			76	0	84	160
17 GA	M	Jul-81	N foot	3A2M	141	80	0	94	174			70	0	94	164
25 LR	M	Sep-75	N foot	7A11M	87	78	0	90	168			72	0	90	162
26 GC	F	Jun-79	N 3 foot	3A4M	283	82	0	86	168			66	0	90	156
29 LM	M	Jan-80	N foot	5A0M	244	78	0	86	164			72	0	86	158
MEAN		Jan-84		5A8M	122.9	76.2	2.7 90	169.7				75.5	0	90.2	165.7

DCAA: distal cuneiform articular angle during the preoperative period; DCAAf: distal cuneiform articular angle at the end of the follow-up; Diag: diagnosis; Age s: surgical age; DOB: date of birth; FMCA: first metatarsal cuneiform angle during the preoperative period; P: metatarsal-cuneiform aperture angle during the preoperative period; FMCAc: first metatarsal cuneiform angle during the immediate postoperative period; FMCAf: first metatarsal cuneiform angle at the end of the follow-up period; Pac: patient; Pc: metatarsal-cuneiform aperture angle during the immediate postoperative period; Pf: metatarsal-cuneiform aperture angle at the end of the follow-up period; N foot: normal foot; PMAA: preoperative metarsal articular angle; PMAAf: metatarsal articular angle at the end of follow-up; CF R: right idiopathic metatarsus adductus as a sequelae of right clubfoot; CF R-B: right idiopathic metatarsus adductus as a sequlae of right clubfoot (originally bilateral); CF L-B: left idiopathic metatarsus adductus as a sequelae of left clubfoot (originally bilateral); Sex: sex; t (m): time of follow-up (months).

Healthy Foot

The results may be seen in Tables 1 and 2 and in Figures 9 and 10.

The FMCA decreased from 169.7° during the preoperative period to 165.7° (‰FMCA-4.0°) at the end of follow-up. The DCAA decreased from 76.2° to 75.5° (‰DCAA –0,7°) and the MCAA angle decreased from 2.7° to 0° (‰MCAA –2,7°). And the PMAA increased from 90° to 90.2° (+0.2°).

DISCUSSION

In MTA there is a medial deviation of the forefoot at the level of the tarsal-metatarsal joint, and the main abnormality is located in the medial metatarsal-cuneiform joint. Farsetti et al[3] discovered that this angle showed greater obliquity in most patients with MTA, although they were not able to correlate it to the pathogenesis of this deformity. Persistent or recurrent MTA is attributed to lack of correc-

Document downloaded from http://www.elsevier.es, day 24/05/2013. This copy is for personal use. Any transmission of this document by any media or format is strictly prohibited.

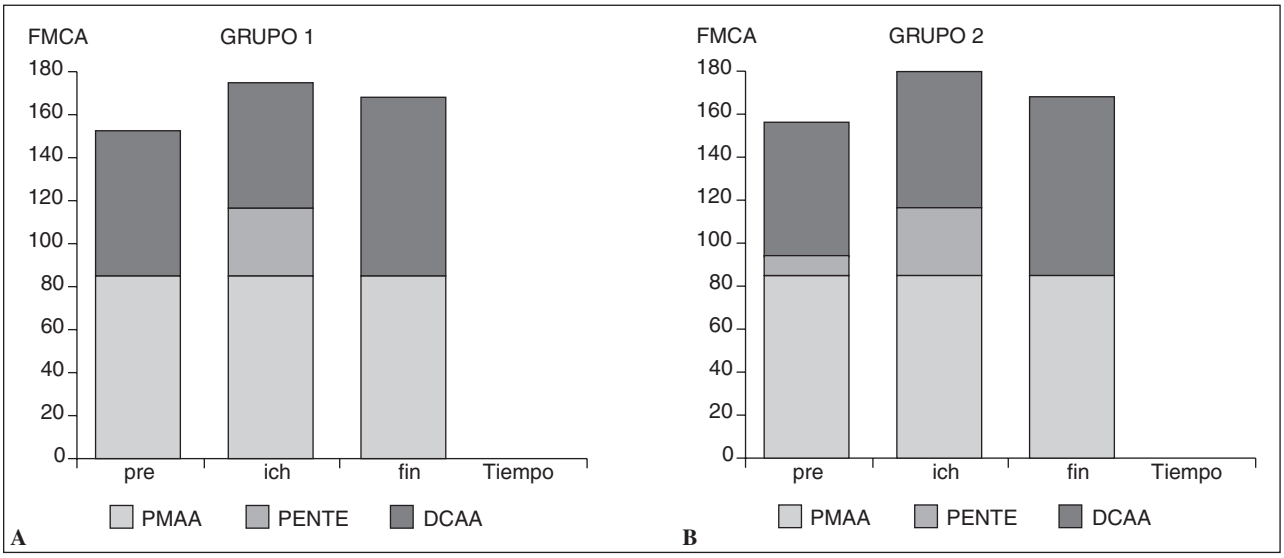

Figure 9. *Graph of the results seen in the operated foot in group 1 (A) and 2 (B). Pre, peri and post operative evolution of the angles of the affected foot. It is possible to see that the increase of the metatarsal-cuneiform angle is basically due to the cuneiform filling in, and that the metatarsal angle remains invariable. DCAA: distal cuneiform articular angle during the preoperative period; FMCA: first metatarsal cuneiform angle during the preoperative period; MCAA: metatarsal-cuneiform aperture angle; PMAA: proximal metatarsal articular angle during the preoperative period.*

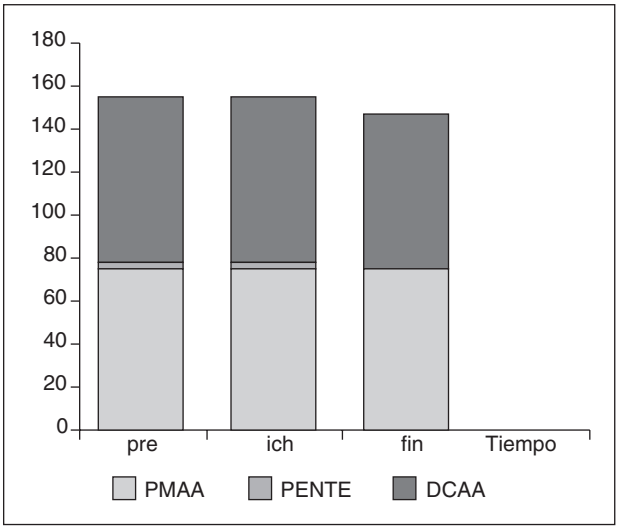

Figure 10. *Graph of the results seen in control feet. Pre, peri and post operative evolution of the angles of the foot non-operated side. It is possible to see that the angles are practically invariable. DCAA: distal cuneiform articular angle during the preoperative period; FMCA: first metatarsal cuneiform angle during the preoperative period; MCAA: metatarsal-cuneiform aperture angle; PMAA: proximal metatarsal articular angle during the preoperative period.*

tion of this obliquity in MTA seen in patients treated for clubfoot[10].

Dykyj et al[11] in their geometric 3D study of the surfaces of the metatarsal-cuneiform joint found significant alterations in the shape of the wedge, which is less rounded in cases of MTA, when compared to the healthy foot.

Our study has allowed us to come to the following conclusions:

1) FMCA is a good measurement of MTA. During the preoperative period, the FMCA is decreased in children with this deformity, both in idiopathic and secondary cases. There is a difference of 19.3° between the FMCA in control feet and the FMCA in idiopathic cases, this difference is significant. We came to the same conclusion when comparing the FMCA in control feet and the FMCA in cases with secondary MTA, where the difference is 14.4° and is also significant.

2) MTA is directly related to the obliquity of the medial metatarsal-cuneiform joint. The difference seen in the FMCA between control feet and affected feet (19.3° in group 1, and 14.4° in group 2) is explained by the decrease of DCAA in any group, either with the idiopathic or secondary condition, (14.2° in group 1, and 14.3° in group 2), and is significant; whereas the variation of the angle of the base of the first metatarsal cannot be explained: (PMAA) (1.6° in group 1, and 1.7° in group 2), which is not significant.

3) Cahuzac's surgical technique is effective in the correction of MTA. This correction is achieved by activation of growth of the first cuneiform that corrects the DCAA. The evolution over time of MTA, that is to say the FMCA in operated children, is more important when compared with the evolution of the same angle in the control feet (‰FMCA group 1 = 19.8°; ‰FMCA group 2 = 14.4°; control = –4.0°), and is statistically significant. This can be explained by to the evolution of the obliquity of the distal angle of the first cuneiform (‰DCAA group 1 = 19.1°; ‰DCAA group 2 = 17.8°; control = –0.7°), which is significant, and not by the evolution of the base of the first metatarsal (‰PMAA group 1 = 0.7°; ‰PMAA group 2 = 1.7; control = 0.2),

Document downloaded from http://www.elsevier.es, day 24/05/2013. This copy is for personal use. Any transmission of this document by any media or format is strictly prohibited.

which is not significant, in any group, either with an idiopathic or a secondary condition.

4) Reactivation of the growth of the first cuneiform tends to fill in the space created by the surgery. Progressive normalization of the MCAA angle during the course of follow-up has significant correlation with the variation of the DCAA seen during the first period. On the contrary, there is no correlation with the MCAA angle, and this lack of correlation is significant in relation to the evolution of the PMAA angle.

All of which allows us to state that the deformity of the first cuneiform that causes medial metatarsal-cuneiform obliquity, has a major role in the pathogenesis of MTA, and that it is this also this bone, and not the first metatarsal, that remodels the joint. But, how does this take place? By what mechanism?

The fist cuneiform is one of the bones with a spherical growth plate that grows from the centre towards the periphery; the base of the first metatarsal, on the contrary, has a rectangular growth plate.

According to Delpech's Law and studies carried out by Hueter-Volkmann[12] on symmetrical compression of growth plates, pressure exerted on a growth plate will cause a decrease of its activity and the contrary is also true, if there is a decrease of pressure on the growth plate, its activity will increase. Frost[12] confirmed this hypothesis with his studies of self aggravation of scoliosis. Roaf[12] further developed this hypothesis with his work on asymmetric compression of the growth plate, and stated that slight pressure on the growth plate increases its activity, while exaggerated pressure decreases it markedly. This phenomenon of stimulation by absence of pressure was confirmed by experiments performed by NASA in gravity free environments[12].

In any case, it would seem that in MTA there is asymmetric compression of a spherical growth plate (cuneiform) and symmetric compression of a rectangular growth plate (base of the first metatarsal). This may be the cause of the deformity which affects the orientation of the joint surface of the first cuneiform, whereas the orientation of the first metatarsal is normal (causing, in consequence, the obliquity of the metatarsal-cuneiform joint), and postoperative remodeling may also be due to the same phenomenon.

Isolated MTA tends to achieve spontaneous correction[2-4]. However, Rusforth[4] in a prospective study of 130 cases of MTA followed up for 7 years, determined that there is persistence of a residual moderate deformity in 10% of cases, and that in 4% of cases there is severe and rigid MTA. On the other hand, he underlines that cases of resistant MTA are not detected until 3 years of age. Widhe[2], in a prospective study carried out on 2,401 newborns, found an incidence of MTA of 3.1%, and this was the most frequent foot deformity he found. At 6 years of age, this author saw spontaneous correction in 87% of cases, and at 16 years of age a persistent metatarsal adduction in 5% (3 cases). These studies confirm the persistence of residual adduction in approximately 5-10% of cases of the isolated form.

In cases of clubfoot sequelae, metatarsal adduction is much more frequent, whatever treatment is applied. The frequency of this condition is estimated at 16-81% according to different series[5,6].

Whatever the origin of MTA (isolated or secondary), residual adduction occurs in Lisfranc's joint. Although it is true that secondary adduction to clubfoot may also partly originate in the talonavicular joint and the deviation of the neck of the talus[13]. In all cases, if we only wish to measure MTA, we will have to use FMCA alone, as we have done in this study.

Although the pathophysiology of MTA is still unknown, it is advisable to note that numerous anatomical and radiological descriptions[3,14-19] coincide in noting that there are abnormalities in the shape and size of the first cuneiform associated with postero-medial obliquity of the medial metatarsal cuneiform joint.. Reimann and Werner[18] in their study carried out of an autopsy of a newly-born with MTA and microcephaly saw that the first cuneiform was smaller and that the articular surface of the first metatarsal was flattened. Morcuende and Ponseti[15] have also analyzed 2 cases of MTA in 2 fetuses of 16 and 19 weeks, and saw that the first cuneiform was deformed and that the medial metatarsal-cuneiform joint was inclined to medial, whereas the other cuneiforms, metatarsals and cuboid bones presented no abnormality. As to radiometry, Gordon et al[17] measured the respective lengths of the first cuneiform and the cuboid bones in 50 feet suffering MTA subsequent to clubfoot, and saw that the first cuneiform was smaller, and also established that a relation existed between the length of the internal and external columns of the foot.

We have not found any alterations or variations of the angle of the base of the first metatarsal, so that our study does not support the observations made by Hyer[20,21], who considers that the obliquity of the base of the first metatarsal is the cause of MTA.

Different pathogenic mechanisms have been considered to explain the modifications of the shape of the cuneiform, such as, for example, intrauterine subluxation of the tarsal-metatarsal joint of the foot[14]; anomalies or excessive traction of the muscular insertions of the *tibialis anterior*, *tibialis posterior* or abductor of the *hallux*[10,14,16,22]; or insufficient clubfoot correction[6]. In any case, alteration of the growth of the first cuneiform causes postero-medial inclination of the medial metatarsal-cuneiform joint and adduction of the other metatarsals as a consequence of traction on the inter-metatarsal ligaments. Once these deviations, that are more a consequence than a cause of adduction, are present, they reinforce the residual deformity and must be treated to prevent recurrences.

Many techniques have been proposed for the correction of residual adduction: Heymann and Herndon proposed a

Document downloaded from http://www.elsevier.es, day 24/05/2013. This copy is for personal use. Any transmission of this document by any media or format is strictly prohibited.

release of Lisfranc's joint. However, Stark et al[23], saw, in a series of 48 cases operated using this technique, with a follow-up of at least 9 years, that correction of the deformity was only achieved in 41% of cases and that 50% of patients had pains in the dorsal area of the foot, a discomfort they were not able to correlate to X-ray images of degeneration of the medial metatarsal-cuneiform joint seen in 68% of the feet studied in the long term.

Berman and Gartland[24] proposed the use of multiple metatarsal osteotomies. Holden et al[25] saw that this procedure caused a shortening of the first metatarsal due to epiphysiodesis in 30% of cases.

Napiontek et al[26] performed an isolated osteotomy to elongate and reorient the articular surface of the first cuneiform by means of a graft in 25 children (37 feet) under 4 years of age and achieved correction of adduction in 26 feet; they confirmed that isolated elongation of the internal column corrects *metatarsus adductus*. They also saw hypertrophy of the first cuneiform. However, residual adduction persisted in 16% of cases.

Mc Hale and Lenhart[27], keeping in mind the asymmetric growth of the external and internal columns of the foot, proposed an osteotomy to shorten the cuboid bone and another to elongate and reorient the articular surface of the first cuneiform, using a cuboid bone graft. In 6 patients (7 feet) over 4 years of age they achieved good correction in all but one case. Many authors have used this technique[10,17,28-30], and all have seen how difficult it is to perform surgery to elongate the first cuneiform in young children, especially when they are under 6 years of age, and saw that the risk of recurrence was approximately 10%. There may be early recurrences, related to graft extrusion, which decreases the length of the first cuneiform[17], or late recurrences, due to a soft tissue retraction[30].

Asirvatham and Stevens[16] proposed a dorsal, medial and plantar capsulotomy of the medial navicular-cuneiform and metatarsal-cuneiform joints, together with elongation of the *hallux* abductor and section of the abnormal insertion of the *tibialis anterior* muscle. In their study of this surgical procedure carried out on 12 feet suffering MTA, with a follow-up of 3 years and 6 months, they showed that they achieved good reduction of the talar-metatarsal angle in all but one case.

All these surgical procedures show that correction of residual adduction may be achieved by extemporaneous lengthening of the first cuneiform or by progressive correction of the shape and size of the first cuneiform after capsulotomy. Our study confirms that reactivation of growth of the first cuneiform after capsulotomy of the metatarsal-cuneiform joint achieves correction of the deformity. Moreover, the improvement of the postero-medial inclination of the first metatarsal is due to the growth of the first cuneiform, since the FMCA increases to 19.8° (group 1) and 14.4° (group 2) because the DCAA changes to 19.1° and 17.8°, respectively.

As to the technique of elongation of the internal column[26], residual adduction persists in 16% of cases. We consider that this complication is related to the persistence of metaphsyeal deviation of the second metatarsal. Moreover, Lisfranc's joint has very little mobility on the frontal plane, due to the more posterior position of the second cuneiform, which causes the base of the second metatarsal to be stuck between the first and third cuneiforms. In consequence, a capsulotomy between the first cuneiform and the first metatarsal together with an osteotomy of the base of the second metatarsal[9] makes it possible to reduce metatarsal adduction; this reduction is lasting due to growth reactivation in the first cuneiform.

In conclusion, obliquity of the medial metatarsal-cuneiform joint is closely related to MTA. This obliquity is due to an abnormality of the first cuneiform that causes an inclination of its distal articular surface. Surgical correction by means of medial metatarsal-cuneiform capsulotomy and osteotomies of the middle metatarsals is possible in small children and has effective and lasting results. This correction is carried out, basically, at the expense of the first cuneiform, not the metatarsal, which tends to fill in the joint space created by surgery. Osteotomy of the middle metatarsals helps to reinforce the reduction. Delpech's law seems to explain these adaptive phenomena.

REFERENCES

1. Cook DA, Breed AL, Cook T, DeSmet AD, Muehle CM. Observer variability in the radiographic measurement and classification of metatarsus adductus. J Pediatr Orthop. 1992;12:86-9.
2. Widhe T. Foot deformities at birth: A longitudinal prospective study over a 16-year period. J Pediatr Orthop. 1997;17:20-4.
3. Farsetti P, Weinstein SL, Ponseti IV. The long term functional and radiographic outcomes of untreated and non-operatively treated metatarsus adductus. J Bone Joint Surg Am. 1994;76A:257-65.
4. Rushforth GF. The natural history of hooked forefoot. J Bone Joint Surg Br. 1978;60B:530-2.
5. Uglow MG, Clarke NMP. The functional outcome of staged surgery for the correction of talipes equinovarus. J Pediatr Orthop. 2000;20:517-23.
6. Tarraf YN, Carroll NC. Analysis of the components of residual deformity in clubfeet presenting for reoperation. J Pediatr Orthop. 1992;12:207-16.
7. Petje G, Steinbock G, Schiller C. Radiographic analysis of metatarsus primus varus. 45 feet followed 15 months alter distal metatarsal osteotomy and lateral soft-tissue release. Acta Orthop Scand. 1997;68:567-70.
8. Elsaid AG, Tisdel C, Donley B, Sferra J, Neth D, Davis B. First metatarsal bone: an anatomic study. Foot Ankle Int. 2006;27:1041-8.
9. Cahuzac JP, Laville MD, Sales de Gauzy J, Lebarbier P. Surgical correction of metatarsus adductus. J Pediatr Orthop. Part B. 1993;2:176-81.
10. Lowe LW, Hannon MA. Residual adduction of the forefoot in treated congenital clubfoot. J Bone Joint Surg Br. 1973; 55B:809-13.

Document downloaded from http://www.elsevier.es, day 24/05/2013. This copy is for personal use. Any transmission of this document by any media or format is strictly prohibited.

11. Dykyj D, Ateshian GA, Trepal MJ, MacDonald LR. Articular geometry of the medial tarsometatarsal joint in the foot: comparison of metatarsus primus adductus and metatarsus primus rectus. J Foot Ankle Surg. 2001;40:357-65.
12. Collard-Meynaud P. Etude des déformations angulaires experimentales du radius chez l'agneau (Thèse de Sciences) Université Paul Sabatier de Toulouse, 2001.
13. Main BJ, Crider RJ. An analysis of residual deformity in club feet submitted to early operation. J Bone Joint Surg Br. 1978; 60B:536-43.
14. Reimann I, Werner HH. Congenital metatarsus varus. A sugestion for a possible mechanism and relation to other foot deformities. Clin Orthop. 1975;110:223-6.
15. Morcuende JA, Ponseti IV. Congenital metatarsus adductus in early human fetal development: A histologic study. Clin Orthop. 1996;333:261-6.
16. Asirvatham R, Stevens P. Idiopathic forefoot-adduction deformity: medial capsulotomy and abductor hallucis lengthening for resistant and severe deformities. J Pediatr Orthop. 1997;17:496-500.
17. Gordon JE, Luhmann SJ, Dobbs MB, Szymanski DA, Rich MM, Anderson DJ, et al. Combined midfoot osteotomy for severe forefoot adductus. J Pediatr Orthop. 2003;23:74-8.
18. Reinmann I, Werner HH. The pathology of congenital metatarsus varus. A post-morten study of a newborn infant. Acta Orthop Scand. 1983;54:847-9.
19. Jawish R. Ostéotomie d'ouverture du premier cunéiforme dans le traitement du varus tarso-metatarsien chez l'enfant. Rev Chir Orthop. 1994;80:131-4.
20. Hyer CF, Philbin TM, Berlet GC, Lee TH. The oblicuity of the first metatarsal base. Foot Ankle Int. 2004;25:728-32.
21. Hyer CF, Philbin TM, Berlet GC, Lee TH. The incidence of the intermetatarsal facet of the first metatarsal and its relationship to metatarsus primus varus: a cadaveric study. J Foot Ankle Surg. 2005;44:200-2.
22. Browne RS, Paton DF. Anomalous insertion of the tibialis posterior tendon in congenital metatarsus varus. J Bone Joint Surg Br. 1979;61:74-6.
23. Stark JG, Johanson JE, Winter RB. The Heyman-Herndon tarsometatarsal capsulotomy for metatarsus adductus: results in 48 feet. J Pediatr Orthop. 1987;7:305-10.
24. Berman A, Gartland JJ. Metatarsal osteotomy for the correction fo adduction of the fore part of the foot in children. J Bone Joint Surg Am. 1971;53A:498-505.
25. Holden D, Siff S, Butler J, Cain T. Shortening of the first metatarsal as a complication of metatarsal osteotomies. J Bone Joint Surg Am. 1984;66A:582-7.
26. Napiontek M, Kotwicki T, Tomaszewski M. Opening wedge osteotomy of the medial cuneiform before age 4 years in the treatment of forefoot adduction. J Pediatr Orthop. 2003;23:65-9.
27. McHale K, Lenhart M. Treatment of residual clubfoot deformity -the «Bean-Shaped» foot- by opening wedge medial cuneiform osteotomy and closing wedge cuboid osteotomy. Clinical review and cadaver correlations. J Pediatr Orthop. 1991;11:374-81.
28. Lourenco AF, Dias LS, Zoellick DM, Sodre H. Treatment of residual adduction deformity in clubfoot: the double osteotomy. J Pediatr Orthop. 2001;21:713-8.
29. Pohl M, Nicol RO. Transcuneiform and opening wedge medial cuneiform osteotomy with closing wedge cuboid osteotomy in relapsed clubfoot. J Pediatr Orthop. 2003;23:70-3.
30. Schaeffer D, Hefti F. Combined cuboid / cuneiform osteotomy for correction of residual adductus deformity in idiopathic and secondary club feet. J Bone Joint Surg Br. 2000;82B: 881-4.

Conflict of interests

The authors have declared they have no conflict of interests.